

Conclusion

The objective set was to prevent amputation of the foot, ensure the wellbeing and comfort of the patient and of the family. The method used began to bear fruit already seven days after the treatment started, with visible changes in the development of the wound.

Analytical and culture checks were carried out regularly to ensure exhaustive monitoring of the infection, glycaemia and other analytical values to ensure proper planning and performance of the ongoing care.

The wound closed ten months after the treatment was started.

Biatain® Ag Non-Adhesive
 Superior absorption – for infected wounds with extra fragile skin

Biatain Ag

Non-Adhesive Foam Dressings with silver



	Item no.	
5x7	5105	
10x10	9622	
15x15	9625	
5x8 cavity	9628	

For product availability/orders, please contact Coloplast on 1800 673 317 or your distributor. Further information at www.coloplast.com.au

References: 1. Ip et al. Antimicrobial activities of silver dressings: an in vitro comparison. *Journal of Medical Microbiology* 2006;(55):59-63. 2. Basterzi et al. In-vitro comparison of antimicrobial efficacy of various wound dressings. *Wounds* July 2010. 3. Münter et al. Effect of a sustained silver-releasing dressing on ulcers with delayed healing: the CONTOP study. *Journal of Wound Care*. 2006;15(5):199-206. 4. Schwarzkopf et al. The release of silver ions from foam dressings. *Wound Management* January 2010. 5. Buchholtz. An in-vitro comparison of antimicrobial activity and silver release from foam dressings. Poster presented at Wounds UK 2009, Wound Care Conference Harrogate. 6. Jørgensen et al. The silver-releasing foam dressing, Contreet Foam, promotes faster healing of critically colonised venous leg ulcers: A randomised, controlled trial. *International Wound Journal*. 2005;2(1):64-73.

Ostomy Care
 Urology & Continence Care
 Wound & Skin Care



Coloplast develops products and services that make life easier for people with very personal and private medical conditions. Working closely with the people who use our products, we create solutions that are sensitive to their special needs. We call this intimate healthcare. Our business includes ostomy care, urology and continence care and wound and skin care. We operate globally and employ more than 7,000 people.


The Coloplast logo is a registered trademark of Coloplast A/S. © 2012-12. WOU146
 All rights reserved Coloplast A/S, 3050 Humlebæk, Denmark.

Coloplast Pty Ltd
 33 Gilby Road
 Mount Waverley
 VIC 3149 Australia

www.coloplast.com.au

Biatain® Ag Non-Adhesive

Case study



Diabetic foot saved from amputation
 – 10 months treatment with Biatain Ag
 Non-Adhesive foam dressing

Biatain® – the simple choice

Case study

Diabetic foot saved from amputation – 10 months treatment with Biatain® Ag Non-Adhesive foam dressing

Authors: Juan Miguel Aranda, Monica Alcaide, José Manuel Sanchez Primary health care nurses. CAP Sant Llútz del Consorci Sanitari de Terrassa (Barcelona).

Introduction

A breach in the skin caused by an ulcer is a portal for the entry of germs. In diabetics, the diminished response of white blood cells in quantitative and qualitative terms fosters infection. Aggravation and loss of feeling means that the patient may walk on infected tissue without being aware of it. This may escalate to more serious levels, worsening the condition of the wound and the patient. 40-50% of diabetic patients develop ulceration of the foot in the course of their life and of those, 14-20% experience amputation.

An ulcerated diabetic foot is a foot with suppuration, malodour, local necrosis, associated with two or more signs of perilesional inflammation (reddening,

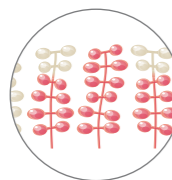
heat, pain, induration, pain when pressed), or osteomyelitis proved by imaging.

Other causes of inflammation must be eliminated such as Charcot's neuro-arthropathy, breaks, thrombophlebitis, gout, lipoderm atosclerosis, etc.

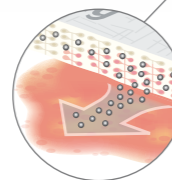
A highly complex case of a diabetic foot calling constituting a major challenge for the nursing team is set out below. For all treatment, it is crucial to follow a personal care plan that coordinates the actions of all the members of the multidisciplinary medical history team. The success in this case was the result of perseverance by the team combined with the actions of family members and the effectiveness of the materials used.

Major independent studies^{1,2} have conclusively proved that Biatain Ag is the only wound dressing that is effective on all bacteria commonly found in infected non-healing wounds.

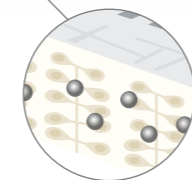
Ensuring the fastest kill of all bacteria and superior absorption, Biatain Ag is both cost-effective and the best dressing for infected wounds¹⁻⁶.



Optimal healing environment^{3,6}
Unique 3D polymer foam structure ensures superior absorption and high retention even under compression therapy.



Rapid killing of bacteria^{1,2,4}
Optimal concentration of silver ensures faster killing of bacteria such as MRSA, VRE, ESBL and Pseudomonas.



Designed to prevent wound infection¹⁻⁶
Our patented silver profile provides you with a sustained release of silver at an effective rate during the entire wear time (up to 7 days).

Materials used

Biatain Ag foam dressings are highly absorbent, soft and conformable antibacterial polyurethane foam dressings that provide an optimal moist wound healing environment and effective exudate management.

Biatain Ag combines superior absorption with controlled and continuous silver release, at an effective rate. An antibacterial ionic silver complex is homogeneously dispersed within the foam and silver ions are released to the wound bed when wound exudate is absorbed into the dressing.

Biatain Ag foam dressings are protected with semi-permeable top films that are waterproof and provide bacterial barriers.

Biatain Ag Non-Adhesive foam dressings are suitable for use on fragile skin due to the absence of adhesive.

Wound Progress

Once the diagnosis of grade 4-5 infected diabetic foot had been confirmed, systematic treatment with oral antibiotics monitored by the family doctor and strict temperature control, carried out by family members, was started to prevent the risk of generalised septicaemia. A daily home care plan for the nursing team was drawn up calling for a high degree of consistency, patience and dedication, and counting on the family's commitment to cooperation in the light of the risk of amputation. The care began with mechanical debridement and extraction of part of the necrotic, slough and suppurative skin and was then treated with enzymatic and autolytic debridements. The dressing used from the beginning was Biatain Ag due to the good exudate management properties and antimicrobial properties in one dressing.

Additionally Biatain Ag had the right density to alleviate pressure. When the treatment was first started, an alginate was used in the cavities to ensure effective management of the exudate and prevent maceration of the edges.

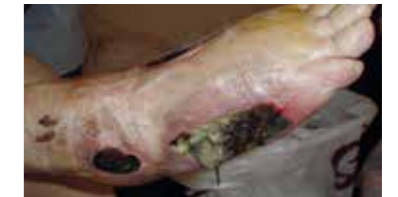

Figure 1. The ulcer at inclusion.

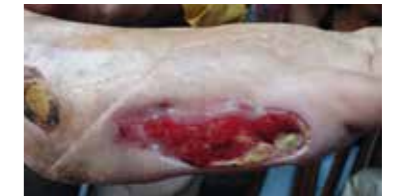

Figure 2. The ulcer after 5 weeks treatment.

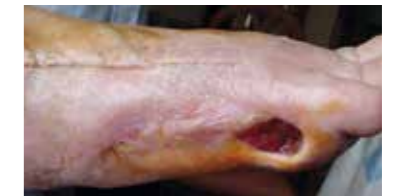

Figure 3. The ulcer after 4 months treatment.

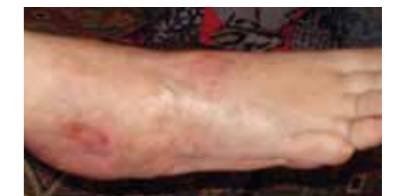

Figure 4. Closed ulcer after 10 months treatment

Medical history

Suffering from heart failure, coronary heart disease, arterial hypertension and venous insufficiency in both lower limbs, as well as Alzheimer's. Not suffering from dislipemia or drug allergies. For four months, she had a very deep wound on the right foot with erythema, oedema, crepitation and heat in the surrounding tissues. It should be pointed out that the patient was not aware of the seriousness of the process since she was suffering from disorientation in space and time and was in a wheelchair. She was referred to the A&E department and after examination by Vascular Surgery, her family was informed that the immediate treatment would involve supracondylar amputation since she was suffering from a grade 4-5 diabetic foot (Figure 1) based on the Wagner scale. The family was opposed to this treatment and the patient was returned to her home for monitoring by her family doctor and out-patient care and dressing by home nursing.