

# Diabetic foot ulcers – prevention and treatment

A Coloplast quick guide



# Table of contents

Introduction .....	3
The diabetic foot – a clinical challenge .....	5
Pathway to clinical care and clinical evidence .....	6
How to prevent diabetic foot ulcers (DFU's).....	7
Prevention and education .....	7
Prevention of ulcer formation .....	8
An interprofessional team approach.....	9
The patient's role .....	10
Consider the whole patient to ensure effective care .....	11
How to diagnose and assess a diabetic foot ulcer .....	12
“The VIPS” of diabetic foot management.....	12
Local wound assessment .....	13
Types of neuropathy .....	14
10-g monofilament testing .....	15
Areas at-risk for neuropathic, ischemic and neuro-ischemic ulcers.....	16
Clinical symptoms of neuropathic and ischemic foot ulcers .....	17
Ulcer assessment .....	18
Wound bed.....	19
Superficial and deep infection symptoms.....	20
Wagner classification .....	21
How to treat a diabetic foot ulcer.....	22
Treatment of diabetic foot ulcers .....	22
Local wound treatment .....	23
Coloplast solutions for diabetic foot ulcers .....	24
Coloplast antimicrobial dressings for infected diabetic foot ulcers and ulcers at-risk of infection.....	26
References .....	28
Coloplast products for diabetic foot ulcers.....	30
Other Coloplast products for diabetic foot ulcers .....	31

## Introduction

Diabetic foot ulcers have a considerable negative impact on patients' lives, and are highly susceptible to infection that all too often leads to amputation. It is essential that diabetic foot ulcers receive the best possible wound management. Successfully treating a diabetic foot ulcer requires a comprehensive understanding of the wound: its cause, progression, risk, and treatment. But more than this, it takes a cross functional approach, where the patient also has an active role in the treatment process.

The information provided here is intended as a general guideline. Please consult diabetic foot ulcer guidelines applicable in your area. For further information, please refer to the International Consensus on the Diabetic Foot, 2011.<sup>2</sup>

We hope that this quick guide will help you diagnose, assess and treat diabetic foot ulcers in clinical practice, as well as identify opportunities for prevention and minimizing the risk of infection and amputation.

### Developed by

Faculty panel: Dr. Christian Munter, Germany; Professor Patricia Price, UK; Wilma Ruigrok van der Werven, MA, RN, Netherlands; Professor Gary Sibbald, Canada

Review panel: Patricia Coutts, RN, Canada; Mike Edmonds, Consultant Diabetologist, UK; Professor Keith Harding UK; Maria Mousley, AHP, Consultant, Podiatrist, UK

This Coloplast quick guide was updated in March 2012 in collaboration with Dr. Christian Munter.

“I marvel that society would pay a surgeon a fortune to remove a person’s leg – but nothing to save it!”

George Bernard Shaw

## The diabetic foot – a clinical challenge

Diabetes is a serious chronic disease that needs attention. Approximately 15% of all people with diabetes will be affected by a foot ulcer during their lifetime.<sup>1</sup>

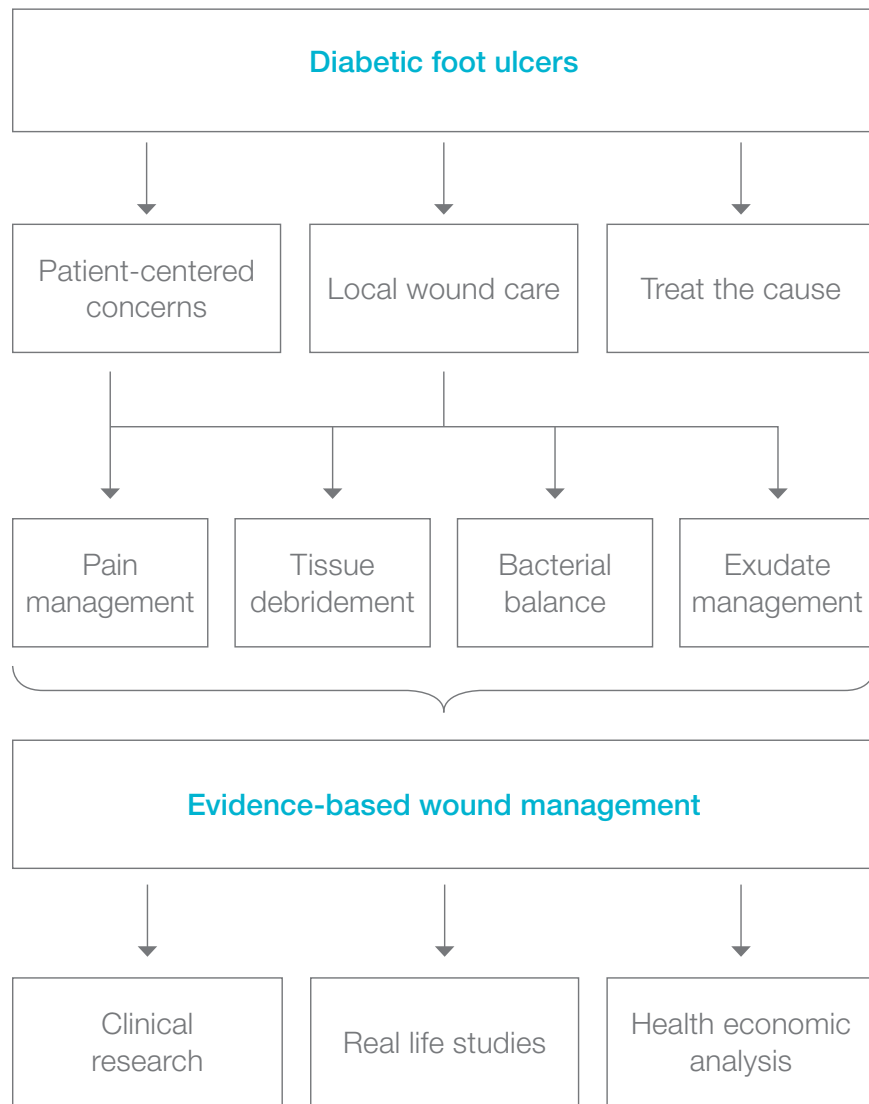
Diabetic foot ulcers (DFUs) often co-exist with vascular insufficiency and are the major cause of gangrene and amputation in people with diabetes. Risk of developing diabetic foot ulcers is greatly increased by reduced sensation and blood perfusion.

Diabetic foot ulcers represent a huge risk to the patient’s quality of life, escalating wound/infection management and costs, and account for a large proportion of all national healthcare budgets.

- Five-year recurrence rates of diabetic foot ulcers are 70%<sup>2</sup>
- Up to 85% of all amputations in relation to people with diabetes are preceded by a diabetic foot ulcer<sup>1-2</sup>
- People with diabetes with one lower limb amputation have a 50% risk of developing a serious ulcer in the second limb within 2 years<sup>3</sup>
- People with diabetes have a 50% mortality rate in the 5 years following the initial amputation<sup>4</sup>

It is possible to reduce amputation rates by 49-85% through a care strategy that combines prevention, the interprofessional diabetes care team, appropriate organization, close monitoring and education.<sup>1</sup>

# Pathway to clinical care and clinical evidence



# How to prevent DFUs

## Prevention and education

*"49-85% of all diabetic foot related problems are preventable."*

**Spraul, M., 2000.<sup>6</sup>**

*"This can be achieved through a combination of good foot care, provided by an interprofessional diabetes care team, and appropriate education for people with diabetes."*

**Modified from Bakker, K. et al., 2005.<sup>1</sup>**

*"Education of patients, carers, and healthcare providers is an essential component of an effective, interprofessional team approach, ...but effective systems and structures for screening, provision of chiropody (podiatry), and footwear, and prompt treatment when required must be in place."*

**Modified from Spraul, M., 2000.<sup>6</sup>**

*"The most important aspects, for example, danger signs which require prompt action by the patient, should be summarized and repeated."*

**Spraul, M., 2000.<sup>6</sup>**

*"Successful diagnosis and treatment of patients with chronic wounds involve holistic care and a team approach. The integration of the work of an interprofessional care team that includes doctors, nurses and allied health professionals with the patient, family and caregivers offers an optimal formula for achieving wound resolution."*

**Sibbald, R.G., et al, 2001.<sup>18</sup>**

## Prevention of ulcer formation

People with diabetes must inspect their feet regularly, or have a family member or care provider do it on their behalf. Daily inspection is the foundation of diabetic foot ulcer prevention. All wounds and sores should be taken seriously early on.

Regular, gentle cleansing with soapy water, followed by the application of topical moisturizers, helps to keep the skin healthy and better able to resist breakdown and injury.

Shoes should be checked to ensure that they fit properly and offer adequate support. Consider athletic/sports shoes and thick, padded socks. Diabetic socks (unrestrictive on circulation) are also available. In the case of foot deformities or special support needs, custom shoes should be considered.

Minor foot injuries and infections, such as cuts, scrapes, blisters and tinea pedis (athlete's foot), can be unintentionally worsened by home treatments that impede healing. Patients should be reminded to avoid hot soaks, heating pads and harsh topical agents such as hydrogen peroxide, iodine and astringents. Minor wounds should be gently cleansed and treated with topical antiseptics. In addition, a physician should inspect any minor wounds that do not heal quickly.


By reinforcing preventive advice and inspecting the patient's feet at routine follow-ups, the physician can help the patient develop and maintain good foot-care practices.

## An interprofessional team approach

- Dermatologist
- Dietitian
- Endocrinologist
- General practitioner
- Home health nurse
- Interventional radiologist
- Orthopedic surgeon
- Orthotist
- Pharmacist
- Podiatrist
- Rehabilitation team:
  - Occupational therapist
  - Physical therapist
  - Psychiatrist
- Vascular surgeon
- Wound, ostomy, continence nurse

### Others

- Diabetes educator
- Foot care nurse
- Neurologist
- Psychologist



The involvement of the patient as a member of the healthcare team improves patient care outcomes

# The patient's role

## Patient self-exam needs to be part of diabetic foot care and follow-up

Education of patient, family and healthcare providers, such as using an easy-to-understand patient leaflet for education, must be a priority.

- Any cut or open skin should be treated by a qualified healthcare provider immediately
- Inspect and examine the feet and shoes on a daily basis
- Appropriate footwear
- Nails should be cared for by a qualified foot specialist - podiatrist or certified foot care nurse (CFCN)
- Dry skin should be treated with appropriate moisturizers, such as (humectant) creams containing urea and/or lactic acid<sup>18</sup>
- Fungal infections, especially of the toe webs require topical antifungal agents or InterDry® Ag textile with antimicrobial silver complex (see page 31)

Patients should always remember to remove socks and shoes for regular inspection of both feet

# Consider the whole patient to ensure effective care of the foot ulcer

<b>Past history, medications and allergies</b>	Check for medications that may inhibit healing (i.e. steroids, immunosuppressants)
<b>Check for other complications</b>	Neurological, vision, cardiac, renal, vascular
<b>Glycemic* control</b>	Hb (Hemoglobin) A1c < 7.5% (depending on the specific situation of the patient, e.g. medication, risk of hypoglycemia, body weight)
<b>Hypertension* control</b>	< 140/90 mmHg
<b>Clinical obesity* control</b>	BMI < 30 kg/m <sup>2</sup>
<b>Hyperlipidemia* control</b>	Cholesterol < 5.2 mmol/L (200 mg/dL)

\*All 4 are associated with the metabolic syndrome and type 2 onset diabetes. Optimal control of diabetes will improve patient care outcomes.

Disclaimer:

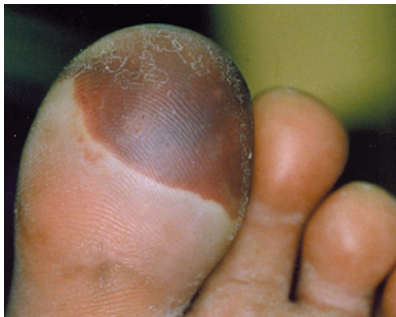These are general guidelines. Please check local treatment recommendations applicable for your healthcare institution.

# How to diagnose and assess a diabetic foot ulcer

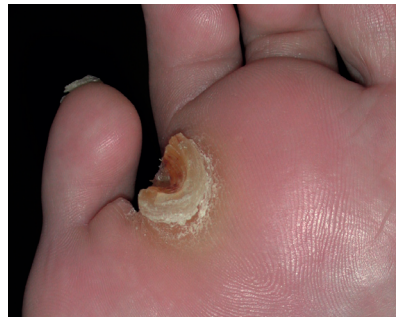“The VIPS”<sup>7,8</sup> of diabetic foot management to ensure outcomes

- V** Vascular supply is adequate
- I** Infection control is achieved
- P** Pressure offloading
- S** Sharp/surgical debridement has been considered

Diabetic foot ulcers typically have a thick rim of keratinized tissue surrounding the wound<sup>9</sup>



Blisters are associated with friction and shear





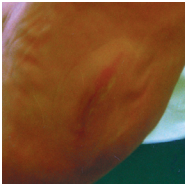
Callus is associated with increased pressure and bleeding

## Local wound assessment<sup>10</sup>

<b>History</b>	<ul style="list-style-type: none"> <li>· Previous ulcer(s), amputations</li> </ul>
<b>Local skin assessment</b>	<ul style="list-style-type: none"> <li>· Edema</li> <li>· Color</li> <li>· Temperature</li> <li>· Callus</li> </ul>
<b>Vascular examination</b>	<ul style="list-style-type: none"> <li>· Check for peripheral arterial disease Symptoms are often not found, but the following signs may be present: cold feet, blanching on elevation, absent hair growth, dry, shiny and atrophic skin<sup>9</sup></li> <li>· Palpate and check for dorsalis pedis, posterior tibial, popliteal and femoral pulses<sup>9</sup></li> <li>· Measure the ankle brachial pressure index (ABPI) Toe pressure or transcutaneous oxygen may be assessed, because arterial calcification can cause falsely elevated ABPI results<sup>9</sup></li> </ul>
<b>Neuropathy</b> <sup>8,11</sup>	<ul style="list-style-type: none"> <li>· Sensory – loss of protective sensation</li> <li>· Autonomic – lack of sweating that results in dry, cracked skin that bleeds and creates a portal of entry for bacteria</li> <li>· Muscular – loss of reflexes or atrophy of muscles that leads to foot deformities</li> </ul>
<b>Deformity and footwear</b>	<ul style="list-style-type: none"> <li>· Charcot foot</li> <li>· Hammer toes, claw toes, bunions</li> <li>· Check the deformity and address inappropriately fitted shoes</li> </ul>



## Types of neuropathy<sup>10</sup>

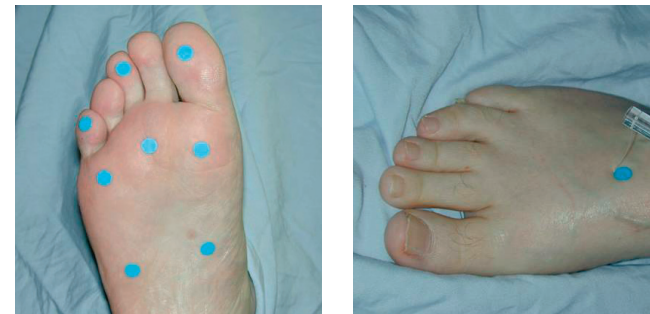Etiology	Sensory neuropathy	Autonomic neuropathy	Motor neuropathy
<b>Characteristics</b>	<ul style="list-style-type: none"> <li>Loss of protective sensation</li> <li>No perception of shoes rubbing or temperature changes</li> </ul>	<ul style="list-style-type: none"> <li>Reduced sweating results in dry cracked skin</li> <li>Increased blood flow leads to a warm foot</li> </ul>	<ul style="list-style-type: none"> <li>Dysfunction of the motor nerves that control the movement of the foot. Limited joint mobility may increase plantar pressure</li> <li>Foot deformities develop</li> <li>Hammer toes</li> </ul>
<b>Clinical presentations</b>	<ul style="list-style-type: none"> <li>Unaware of a foot ulcer or lack of discomfort when a wound is being probed</li> </ul>	<ul style="list-style-type: none"> <li>Dry skin with cracks and fissures</li> <li>Bounding pulses</li> <li>Dilated dorsal veins</li> <li>Warm feet</li> </ul>	<ul style="list-style-type: none"> <li>High medial longitudinal arch, leading to prominent metatarsal heads and pressure points over the plantar forefoot</li> <li>Clawed toes</li> <li>Altered gait</li> </ul>
			

## 10-g monofilament testing

The 10-g/5.07 monofilament testing is recommended as a screening tool to determine the presence of protective sensation in people with diabetes.<sup>11-13</sup>

### Places for testing

- Plantar surface of the metatarsal heads (minimum of 3 metatarsal heads)<sup>12,13</sup>
- The great toe/first toe<sup>12</sup>
- The medial and lateral sides of the plantar aspect of the midfoot<sup>13</sup>
- The plantar area of the heel<sup>13</sup>
- The dorsal aspect of the midfoot<sup>13</sup>



Monofilament testing sites

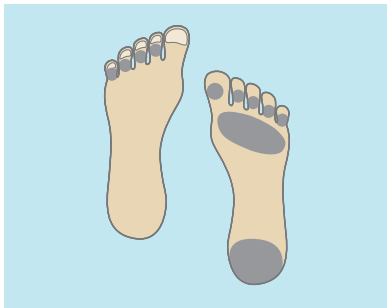*"There is no clear evidence on how many negative response sites equals an at-risk foot. Some literature shows that even one site with a negative response on each foot may indicate an at-risk foot."*

**Baker, N. et al., 2005.<sup>12</sup>**

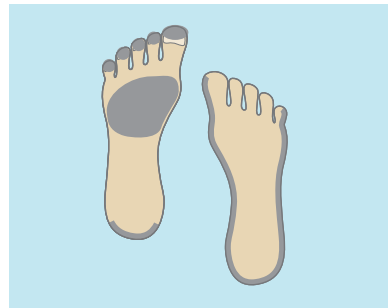

## Areas at-risk for neuropathic, ischemic and neuro-ischemic ulcers

In a cross-sectional, population-based study the proportion of the lesions were\*2:



Neuropathic ulcers 55% of total diabetic foot ulcers




Ischemic ulcers 10% and neuro-ischemic ulcers 34% of total diabetic foot ulcers

*“Recent experience from our clinic indicates that the frequency of neuropathic ulcers has decreased, and the incidence of ischemic and neuro-ischemic ulcers has increased, equaling 50-50%.”*

**Mike Edmonds, 2005.**

\*1% of the ulcers were considered not to be diabetes-related.

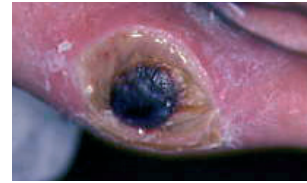## Clinical symptoms of neuropathic and ischemic foot ulcers<sup>14</sup>

Clinical signs	Neuropathic ulcer 	Ischemic ulcer 
Foot deformities	Clawed toes, possible high arch, possible Charcot deformities	No specific deformities. Possible absent toes/forefoot from previous amputations
Foot temperature	Warm	Cold or decreased temperature
Skin color	Normal or red	Pale/bluish. Pronounced redness when lowered (dependent rubor), blanching on elevation
Skin condition	Dry skin due to decreased sweating	Thin, fragile and dry
Ulcer location	On the plantar aspects (forefoot 80%) of the foot/toes	Distal/tips of the toes, heel, or margins of the foot
Callus present	Commonly seen on the weight-bearing areas and is generally thick	Not usually. If present, distal eschar or necrosis
Ulcer characteristics	Usually painless, with a “punched out” appearance (granulation or deeper base) surrounded by callus	Painful, especially with necrosis
Sensation	Reduced or absent sensation to touch, vibration, pain, and pressure	Sensation may be present but decreased if there is associated neuropathy
Ankle reflexes	Usually not present	Usually present
Foot pulses	Present and often bounding. Dilated, prominent veins	Absent or markedly reduced

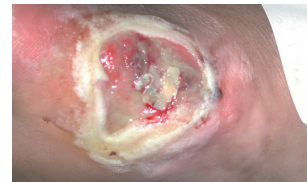## Ulcer assessment

<b>Neuropathic pain</b>	Burning, stinging, shooting and stabbing (non-stimulus dependent)
<b>Local pain</b>	Deep infection or Charcot joint
<b>Size</b>	Length, width, depth and location, preferably with clinical photograph
<b>Wound bed</b>	<b>Appearance</b> <ul style="list-style-type: none"> <li>· Black (necrosis)</li> <li>· Yellow, red, pink</li> <li>· Undermined</li> </ul>
<b>Infection signs</b>	<b>Odor</b> Be aware that some signs (fever, pain, increased white blood count/ ESR) may be absent. Evaluate the ulcer for signs of infection, inflammation and edema. For more information, please see page 20
<b>Exudate</b>	Copious, moderate, minimal, none
<b>Wound edge</b>	Callus and scales, maceration, erythema, edema

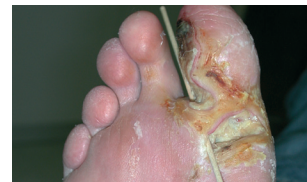## Wound bed



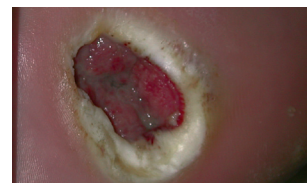Eschar



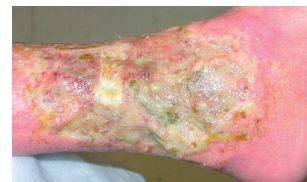Slough



Wound undermining, deep tissue infection



Maceration

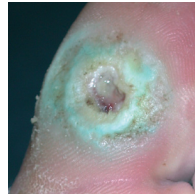


Unhealthy wound edge

## Superficial and deep infection symptoms<sup>10,15,16</sup>

### Superficial (local) – Treat topically

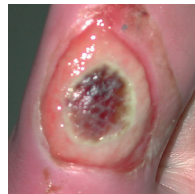- Non-healing
- Exuberant, friable granulation tissue
- Bright red discoloration of granulation tissue
- Increased exudate
- Malodor
- New slough in wound base



Topical antimicrobial treatment may be considered for superficial/local infection, dependent on the assessment that will direct the treatment. Superficial/local infection may, however, require systemic antibiotics. For further details and updates, please see the International Consensus on the Diabetic Foot, 2011.<sup>2</sup>

### Deep – Treat systemically

- Pain
- Probes to bone (increased risk in the presence of osteomyelitis)
- New areas of break-down
- Warmth
- Erythema, edema



Signs of local and deep infection are potentially limb and/or life threatening. These clinical signs and symptoms require urgent medical attention<sup>11</sup>

## Wagner classification

Grade	Ulcer appearance
Grade 0	No open lesions; may have deformity or cellulitis
Grade 1	Superficial diabetic ulcer (partial or full thickness)
Grade 2	Ulcer extension to ligament, tendon, joint capsule, or deep fascia without abscess or osteomyelitis
Grade 3	Deep ulcer with abscess, osteomyelitis, or joint sepsis
Grade 4	Gangrene localized to portion of forefoot or heel
Grade 5	Extensive gangrenous involvement of the entire foot

Further reading:  
International Consensus on the Diabetic Foot, The International Working Group on the Diabetic Foot, 2011<sup>2</sup>, [www.iwgdf.org](http://www.iwgdf.org)

# How to treat a diabetic foot ulcer

## Treatment of diabetic foot ulcers

<b>Vascular</b>	<ul style="list-style-type: none"> <li>· If inadequate circulation, refer to vascular assessment and testing</li> <li>· Consider angioplasty, bypass or amputation</li> </ul>
<b>Infection</b>	<p><i>Bacterial swabs help to identify organisms and sensitivity, but do not diagnose infection in isolation from clinical features</i></p> <ul style="list-style-type: none"> <li>· Superficial/local – consider topical antimicrobial treatment (e.g. sustained silver-releasing dressings). However, it may need systemic antibiotic therapy. The general treatment may also include debridement of devitalized tissue, pressure relief, optimizing metabolic control and vascular intervention<sup>2</sup></li> <li>· Deep – requires systemic antibiotic therapy to initially cover Gram-positive, Gram-negative and anaerobic organisms. Subsequently, systemic antibiotic therapy can be modified according to the results of the culture. In addition, it is essential to consider the need for surgical debridement, drainage of infection, alongside pressure relief and optimizing metabolic control</li> <li>· Topical antimicrobial (e.g. sustained silver-releasing dressings) may give added benefit together with systemic coverage for deep infection</li> </ul>
<b>Pressure</b>	<ul style="list-style-type: none"> <li>· Appropriate offloading must be provided</li> <li>· Total contact cast or pneumatic walker</li> <li>· Deep toed or special shoes and orthotics</li> </ul>

Frequent (dependent on the clinical situation) inspection of the diabetic foot ulcer is vital due to the increased risk of infection

Disclaimer:  
These are general guidelines. Please check local treatment recommendations applicable for your healthcare institution.

## Local wound treatment

<b>Tissue debridement</b>	<ul style="list-style-type: none"> <li>· Surgical sharp surgery preferred</li> <li>· Hydrophilic paste, hydrogels, alginates and enzymes</li> </ul>
<b>Infection</b>	<p>Dependent on the outcomes of the wound assessment:</p> <ul style="list-style-type: none"> <li>· Topical antimicrobials (e.g. sustained silver-releasing dressings)</li> <li>· Systemic antibiotic therapy</li> </ul>
<b>Exudate management</b>	<ul style="list-style-type: none"> <li>· Foams, alginates</li> </ul>
<b>Wound margin management</b>	<ul style="list-style-type: none"> <li>· The treatment of the edge depends on the outcomes of the assessment of the edge of the wound. In general, healthy wounds have a pink wound bed and an advancing wound margin, while unhealthy wounds have a dark and undermined wound margin<sup>11</sup></li> </ul>
<b>Neuropathic pain</b>	<p>Occasionally, neuropathy can be associated with pain. For people with painful diabetic neuropathy, consider the following treatment:</p> <p>Tricyclic antidepressants<sup>7,17</sup> (TCAs):</p> <ul style="list-style-type: none"> <li>· Second generation TCA agents<sup>17</sup> e.g. duloxetine</li> <li>· First generation TCA agent<sup>7,17</sup>: amitriptyline</li> <li>· Anticonvulsants: pregabalin<sup>17</sup></li> </ul>

Application of moisture retentive dressings in the context of ischemia and/or dry gangrene can result in a serious life-or-limb-threatening infection<sup>11</sup>

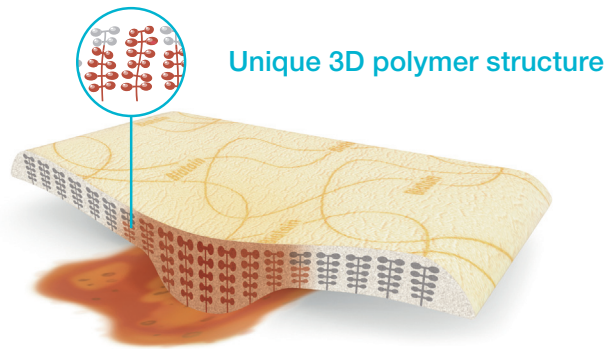
Infection control is of paramount importance in DFU treatment because of its strong association with amputation. A study of 1,666 patients with diabetes found that foot infection increased the risk of amputation by 155 times<sup>19</sup>

Disclaimer:  
These are general guidelines. Please check local treatment recommendations applicable for your healthcare institution.

## Coloplast solutions for diabetic foot ulcers

### Biatain® – The simple choice for superior absorption

Biatain is a soft and conformable foam dressing that effectively absorbs and retains wound exudate.<sup>20,21</sup> This ensures a moisture balance that is optimal for healing of exuding wounds.<sup>22,23</sup>



Unique 3D polymer structure



### Biatain Non-Adhesive – superior absorption for wounds with extra fragile skin

Biatain Non-Adhesive is a soft and flexible absorbent polyurethane foam dressing with bevelled edges.



### Biatain Silicone – superior absorption for general purposes

Biatain Silicone is a soft and flexible absorbent foam dressing with a gentle silicone adhesive only on the border leaving the foam free to absorb exudate and manage the wound.



### Biatain® Soft-Hold – superior absorption for wounds that are difficult to bandage

Biatain Soft-Hold has a gentle adherent layer covering less than 50% of the foam surface. Allows both hands to be free during dressing application and removal.



### SeaSorb® Soft – superior absorption for cavity filling

Highly absorbent alginate dressing for moderate-to-heavy exuding wounds of any size and shape.



### Triad™ Hydrophilic wound dressing

- Natural debrider, safe for periwound edges
- Cost-effective solution
- Light-to-moderate exuding wounds



### Purilon® Gel – Effective and gentle debridement

- Fast and effective debridement
- High cohesion – the gel remains in place



### Atrac-Tain® Cream

Atrac-Tain moisturizing cream is beneficial in the treatment of moderate-to-severe xerosis of the feet in patients with diabetes.<sup>24</sup>



### Sween® 24 Cream

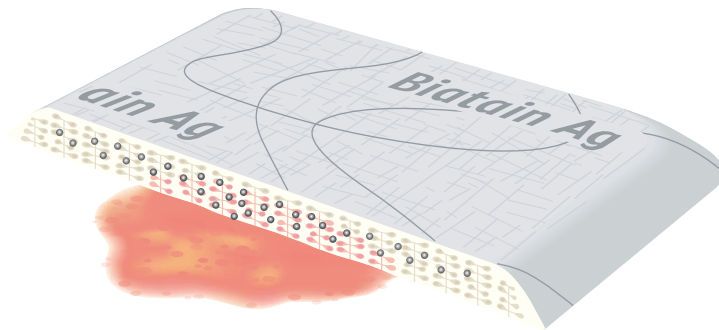
Sween 24 is a 24-hour moisturizer for moderate-to-severe dry skin. Aids with the prevention of xerosis.

## Coloplast antimicrobial dressings for infected diabetic foot ulcers and ulcers at-risk of infection

### Biatain® Ag – superior absorption for infected wounds

Sustained silver activity during the entire wear time (up to 7 days)<sup>25</sup>

- Optimal wound healing environment<sup>26-27</sup>
- Rapid antimicrobial activity<sup>28</sup>
- Solution for wounds at-risk of infection<sup>25,28</sup>



### Biatain® Ag Non-Adhesive – superior absorption for managing infected wounds, infected wounds with extra fragile skin

Biatain Ag is a soft and conformable silver foam dressing that is a proven solution for wounds at-risk of infection.<sup>25,28</sup>



### Biatain Silicone Ag – superior absorption for managing infected wounds

Biatain Silicone Ag is a soft and flexible absorbent silver foam dressing with a gentle silicone adhesive border.



### SeaSorb® Ag – superior absorption for cavity filling on infected wounds

Highly absorbent antimicrobial alginate dressing for moderate-to-heavy exuding infected wounds or wounds at-risk of infection. Conforms to any shape and aids in debridement.

- Designed to fight cavity wound infection
- Effective on a broad range of bacteria<sup>29</sup>

# References

1. Bakker, K. et al. The year of the diabetic foot, *Diabetes Voice*, March 2005, Vol. 50(1): 11-14.
2. International Working Group on the Diabetic Foot, *International Consensus on the Diabetic Foot*, 2007, 2011.
3. Jude, E. et al. Assessment of the diabetic foot. *Chronic Wound Care: Chapter 58*, In: Krasner, D.L. et al., *A Clinical Sourcebook for Healthcare Professionals, Third Edition*, HMP Communications Inc. 2001: 589-597.
4. Armstrong, D.G. et al. Diabetic foot infections: stepwise medical and surgical management. *International Wound Journal*, 2004, Vol. 1(2): 123-132.
5. Williams, R. et al. The size of the problem: Epidemiological and economic aspects of foot problems in diabetes. In: Boulton, A.J.M. et al., *The Foot in Diabetes*, John Wiley & Sons, Ltd., 2000: 3-17.
6. Spraul, M. Education – can it prevent diabetic foot ulcers and amputations? In: Boulton, A.J.M. et al., *The Foot in Diabetes*, John Wiley & Sons, Ltd., 2000: 111-120.
7. Reddy, M. Wound healing: The next millennium. *Diabetic Microvascular Complications Today*, May/June 2005: 25-27.
8. Inlow, S. et al. Best practices for the prevention, diagnosis, and treatment of diabetic foot ulcers, *Ostomy/Wound Management* 2000, Vol. 46(11): 55-68.
9. Frykberg, R.G. et al. A summary of guidelines for managing the diabetic foot. *Advances in Skin & Wound Care* 2005, Vol. 18(4): 209-213.
10. Edmonds, M. et al. *A Practical Manual of Diabetic Foot Care*, Blackwell Science, Oxford 2004.
11. Registered Nurses' Association of Ontario 2005. *Assessment and management of foot ulcers for people with diabetes*. Toronto, Canada: Registered, Nurses' Association of Ontario.
12. Baker, N. et al. A user's guide to foot screening. Part 1: Peripheral neuropathy, *The Diabetic Foot* 2005, Vol. 8(1): 28-37.
13. Browne, A.C. et al. The diabetic neuropathic ulcer: An overview. *Ostomy/Wound Management*, 1999. Vol. 45 (No. 1A: Suppl).
14. Edmonds, M.E. et al. *Managing the Diabetic Foot*, Blackwell Science, Oxford 2005.
15. Sibbald, R.G. et al. Preparing the Wound Bed 2003: Focus on infection and inflammation, *Ostomy/Wound Management*, November 2003, Vol. 49(1): 24-51.
16. Sibbald, R.G. et al. Cost-effective faster wound healing of critically colonized wounds with a sustained release silver foam dressing, based upon the symposium "Bacteria, sustained release of silver and improved healing", An official satellite symposium of the WUWHS 2004. Published at [www.worldwidewounds.com](http://www.worldwidewounds.com) December 2005.
17. CG96 Neuropathic pain - pharmacological management: full guideline, NHS, National Institute for Health and Clinical Excellence, 27 May 2010 (<http://guidance.nice.org.uk/CG96/Guidance/pdf/English>).
18. Sibbald, R.G. et al. Dermatological aspects of wound care, Chapter 30, In: Krasner, D.L. et al., *A Clinical Sourcebook for Healthcare Professionals, Third Edition*, HMP Communications Inc., 2001: 273-285.
19. Lavery et al. *Diabetes Care* 2006;29(6):1288-93.
20. Andersen et al. A randomized, controlled study to compare the effectiveness of two foam dressings in the management of lower leg ulcers. *Ostomy/Wound Management* 2002;48(8):34-41.
21. Thomas et al. [www.dressings.org/TechnicalPublications/PDF/Coloplast-Dressings-Testing-2003-2004.pdf](http://www.dressings.org/TechnicalPublications/PDF/Coloplast-Dressings-Testing-2003-2004.pdf)
22. White R and Cutting KF. Modern exudate management: a review of wound treatments. *WorldWideWounds* 2006.
23. Romanelli et al. Exudate management made easy. *Wounds International* 2010;1(2).
24. Pham et al. A prospective, randomized, controlled double-blind study of a moisturizer for xerosis of the feet in patients with diabetes. *Ostomy/Wound Management* 2002;48(5):30-36.
25. Buchholtz. An in-vitro comparison of antimicrobial activity and silver release from foam dressings. *Wounds UK* 2009.
26. Jørgensen et al. The silver-releasing foam dressing, Contreet Foam, promotes faster healing of critically colonised venous leg ulcers: a randomised, controlled trial. *International Wound Journal* 2005;2(1):64-73.
27. Mürter et al. Effect of a sustained silver-releasing dressing on ulcers with delayed healing: the CONTOP study. *Journal of Wound Care*. 2006;15(5):199-206.
28. Ip et al. Antimicrobial activities of silver dressings: an in vitro comparison. *Journal of Medical Microbiology* 2006;55:59-63.
29. Independent laboratory testing provided by Wickham Laboratories.



# Coloplast® products for diabetic foot ulcers

Superior absorption for non-infected wounds\*

## Biatrain Silicone

Code	Size	Units	HCPCS
3434	3 x 3" (7.5 x 7.5 cm)	10	A6212
3435	4 x 4" (10 x 10 cm)	10	A6212
3436	5 x 5" (12.5 x 12.5 cm)	10	A6212
3437	6 x 6" (15 x 15 cm)	5	A6212
3438	7 x 7" (18 x 18 cm)	5	A6213

## Biatrain Silicone Lite

Code	Size	Units	HCPCS
3444	3 x 3" (7.5 x 7.5 cm)	10	A6212
3445	4 x 4" (10 x 10 cm)	10	A6212
3446	5 x 5" (12.5 x 12.5 cm)	10	A6212

## Biatrain Soft-Hold

Code	Size	Units	HCPCS
3473	2 x 2¾" (5 x 7 cm)	5	A6209
3470	4 x 4" (10 x 10 cm)	5	A6209
3475	6 x 6" (15 x 15 cm)	5	A6210

## Biatrain Non-Adhesive

Code	Size	Units	HCPCS
6105	2 x 2¾" (5 x 7 cm)	10	A6209
3410	4 x 4" (10 x 10 cm)	10	A6209
3413	6 x 6" (15 x 15 cm)	5	A6210
3416	8 x 8" (20 x 20 cm)	5	A6211

## Biatrain Adhesive

Code	Size	Units	HCPCS
3430	4 x 4" (10 x 10 cm)	10	A6212
3420	5 x 5" (12.5 x 12.5 cm)	10	A6212
3423	7 x 7" (18 x 18 cm)	5	A6213
Heel			
3488	7½ x 8" (19 x 20 cm)	5	A6212

Superior absorption for infected wounds\*

## Biatrain Silicone Ag Coming soon

Code	Size	Units	HCPCS
9636	3 x 3" (7.5 x 7.5 cm)	10	A6212
9637	4 x 4" (10 x 10 cm)	10	A6212
9638	5 x 5" (12.5 x 12.5 cm)	10	A6212
9639	6 x 6" (15 x 15 cm)	5	A6212
9640	7 x 7" (18 x 18 cm)	5	A6213

## Biatrain Ag Non-Adhesive

Code	Size	Units	HCPCS
9622	4 x 4" (10 x 10 cm)	5	A6209
9625	6 x 6" (15 x 15 cm)	5	A6210

## Biatrain Ag Adhesive

Code	Size	Units	HCPCS
9632	5 x 5" (12.5 x 12.5 cm)	5	A6212
9635	7 x 7" (18 x 18 cm)	5	A6213
Heel			
9643	7½ x 7¾" (19 x 20 cm)	5	A6212



## SeaSorb Soft Ag

Code	Size	Units	HCPCS
3755	2 x 2" (5 x 5 cm)	30	A6196
3760	4 x 4" (10 x 10 cm)	10	A6196
3765	6 x 6" (15 x 15 cm)	10	A6197

## SeaSorb Soft Ag Alginate Filler

Code	Size	Units	HCPCS
3780	1 x 17.5" rope (44 cm)	10	A6199



Other products for diabetic foot ulcers and skin conditions

## SeaSorb® Soft

Code	Size	Units	HCPCS
3705	2 x 2" (5 x 5 cm)	30	A6196
3710	4 x 4" (10 x 10 cm)	10	A6196
3715	6 x 6" (15 x 15 cm)	10	A6197



## Purilon® Gel

Code	Size	Units	HCPCS
3906	.28 oz/8g	10	A6248
3900	.5 oz/15g	10	A6248
3903	.88 oz/25g	10	A6248



## Atrac-Tain® Cream

Code	Size	Units
1843	2 g single app. pkt	300
1802	2 oz/57 g	12
1814	5 oz/142 g	12



## InterDry® Ag Textile

Code	Size	Units
7910	10 x 44"	10/case
7912	10 x 36"	10 pks/box



## SeaSorb Soft Alginate Filler

Code	Size	Units	HCPCS
3470	1 x 17.5" rope (44 cm)	10	A6199



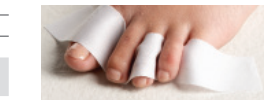## Triad™ Hydrophilic Paste

Code	Size	Units	HCPCS
1964	2.5 fl. oz./71 g	12	A6240
1967	6 oz./170 g	12	A6240



## Sween® 24 Cream

Code	Size	Units
7090	4 g single app. pkt	300
7091	2 oz/57 g	12
7092	5 oz/142 g	12
7095	9 oz/255 g	12



Example of InterDry Ag woven in between the toes

\* Can be used for all types of exuding wounds.

After 30 years in wound care, we at Coloplast believe that absorption is the key to better healing. Our Biatain® portfolio brings superior absorption to daily wound care needs, making Biatain the simple choice for faster healing.

Ostomy Care  
Urology & Continence  
Wound & Skin Care

Coloplast develops products and services that make life easier for people with very personal and private medical conditions. Working closely with the people who use our products, we create solutions that are sensitive to their special needs. We call this intimate healthcare. Our business includes ostomy care, urology and continence care and wound and skin care. We operate globally and employ more than 7,000 people.

The Coloplast logo is a registered trademark of Coloplast A/S.  
© 2012 Coloplast Corp. All rights reserved.



Coloplast Corp.  
Minneapolis, MN 55411  
1.800.533.0464

[www.us.coloplast.com](http://www.us.coloplast.com)

M4007N 04.12